Some Gross Anatomical Relations of the Male Urogenital System and Other Internal Organs in *Eumeces fasciatus*.

ALBERT E. REYNOLDS, DePauw University[1]

Introduction

While the attack on the problems of zoology proceeds with increasing intensity over an ever-widening front, it remains true that, among vertebrates, the reptiles are a relatively neglected group. Phyllogenetic position, physiological considerations centering around poikilothermism, or difficulty of capture or keeping may militate toward this neglect. Another factor may well be that the exact anatomy of most American reptiles has not been worked out. For the experimentalist, therefore, they do not constitute a part of an explored field from which he may select an experimental medium. It is in the hope that a small contribution may be made toward the placing on record of anatomical data on native reptiles that the observations reported here on the red-headed skink, *Eumeces fasciatus*, are presented.

The scincoid *Eumeces fasciatus* may be regarded as a fairly representative American lizard as it has a widespread distribution in the United States (Stejneger and Barbour, 1939; Taylor, 1935). My interest in the animal centered around certain physiological processes and their seasonal variations, approached in part from the standpoint of histological study. For proper prosecution of such studies, a background of knowledge of the gross anatomy had to be developed, and it is to the reporting of some of the gross anatomical relations of these animals that this paper is devoted.

Material

The skinks that have been examined have been adults or animals only slightly immature. While a few of the animals observed have been from the several counties around the Greencastle (Indiana) area, specimens have also been obtained from Arkansas, Missouri, Tennessee, and Florida. The total number of animals that have passed under scrutiny number several score. Such general statements as occur in this paper are based on the total experience gained in working with these animals; the more specific statements are based on five specimens, animal numbers 4, 53, 54, 55, and 210.

Methods

In dissection the usual approach by means of a ventral incision through the body wall was employed. Due to extensive subcutaneous connective tissue, the skin is firmly adherent to the subjacent muscular coat.

---

[1]Approximately half the work upon which this paper is based was done at the Hull Zoological Laboratory, The University of Chicago.

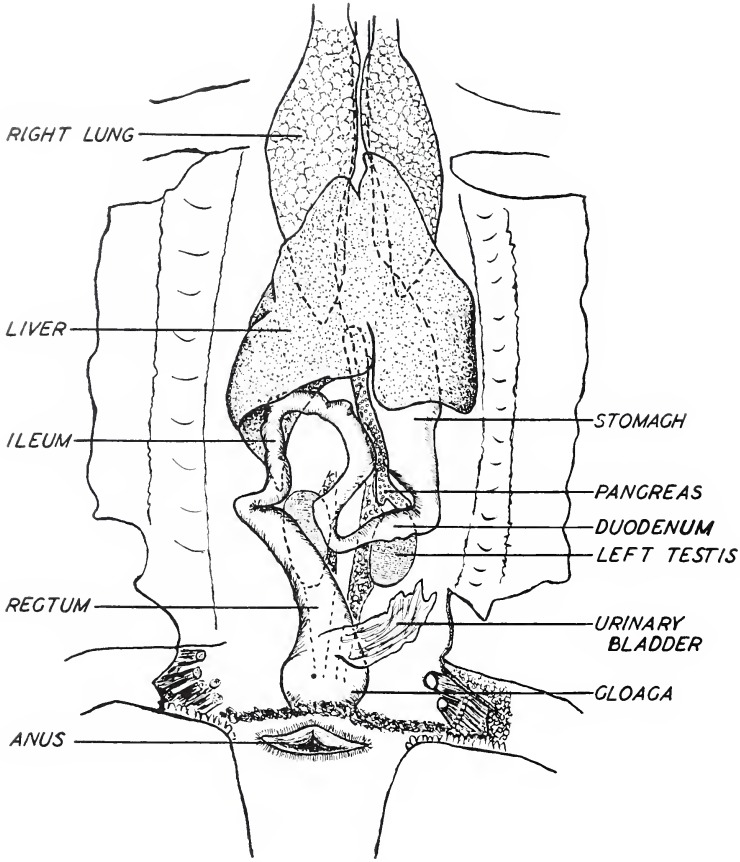

Fig. 1. *Eumeces fasciatus* No. 4. Ventral dissection of young male drawn to scale, showing chief abdominal viscera. For relations, limb outlines, cut muscles, and flaps of body wall tissue shown. (x3)

In *Eumeces fasciatus* the skin is complicated not only by epidermal scales but also by the underlying bony osteoderms of dermal origin. After parting the skin, another incision is passed through the muscular coat (mostly the M. rectus abdominis). Lateral cuts at the limb levels then permitted pinning back of the flaps of body wall tissue. Further dissection, such as removal of muscle, bone, *etc.*, at the girdle levels was carried out as needed.

Figures were drawn to scale, and in each case different degrees of dissection reveal different aspects of the internal anatomy. Figure 1 shows organs visible after opening up the coelom with a minimum of organ displacement. The view seen in Figure 2 required more dissection; that in Figure 3, still more.

Both freshly killed and preserved animals have been examined. All reference to color and appearance is based on the fresh condition. As aids to study, the binocular dissecting microscope and micrometer cali-

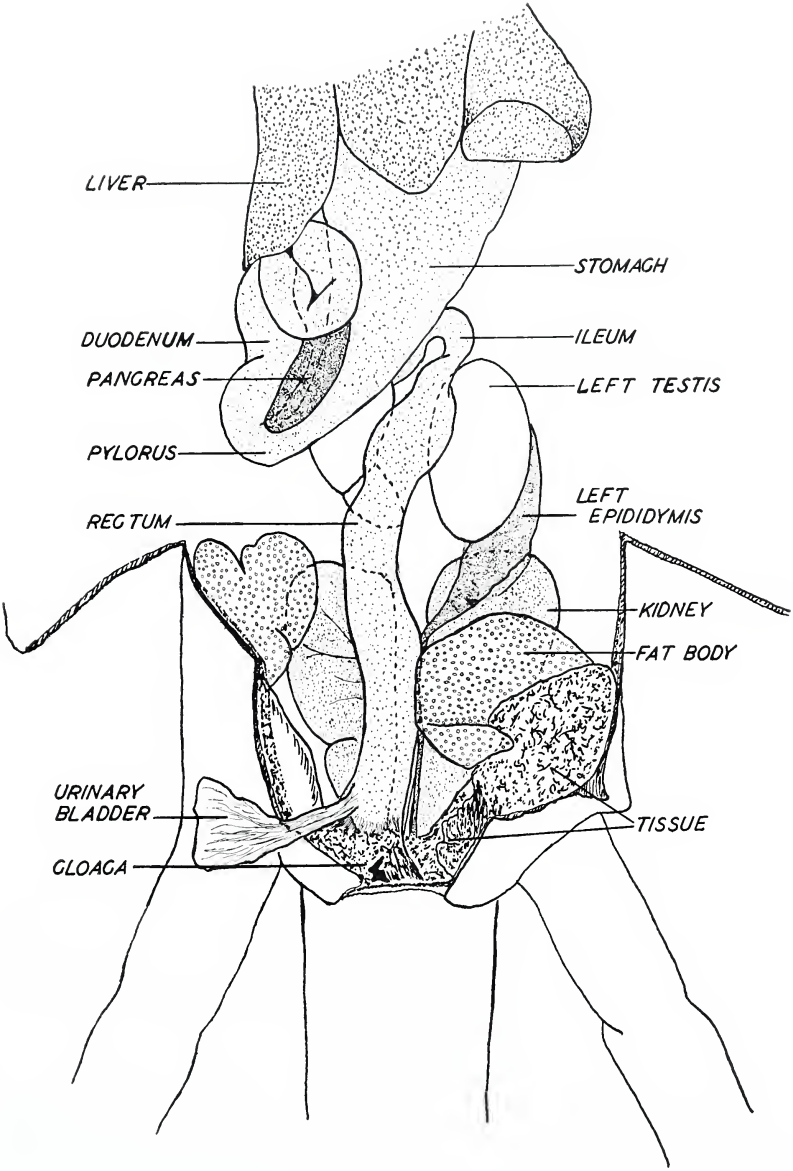

Fig. 2. *Eumeces fasciatus* No. 210. Ventral dissection of mature male, showing part of abdominal viscera and most of urogenital system. Area labelled "tissue" consists of residual cut ends of muscle, connective tissue, *etc.* (x3)

pers were extensively used. Where measurements are expressed in metric units, they do not represent numerical averages or statistical means but are the single measurements of representative specimens.

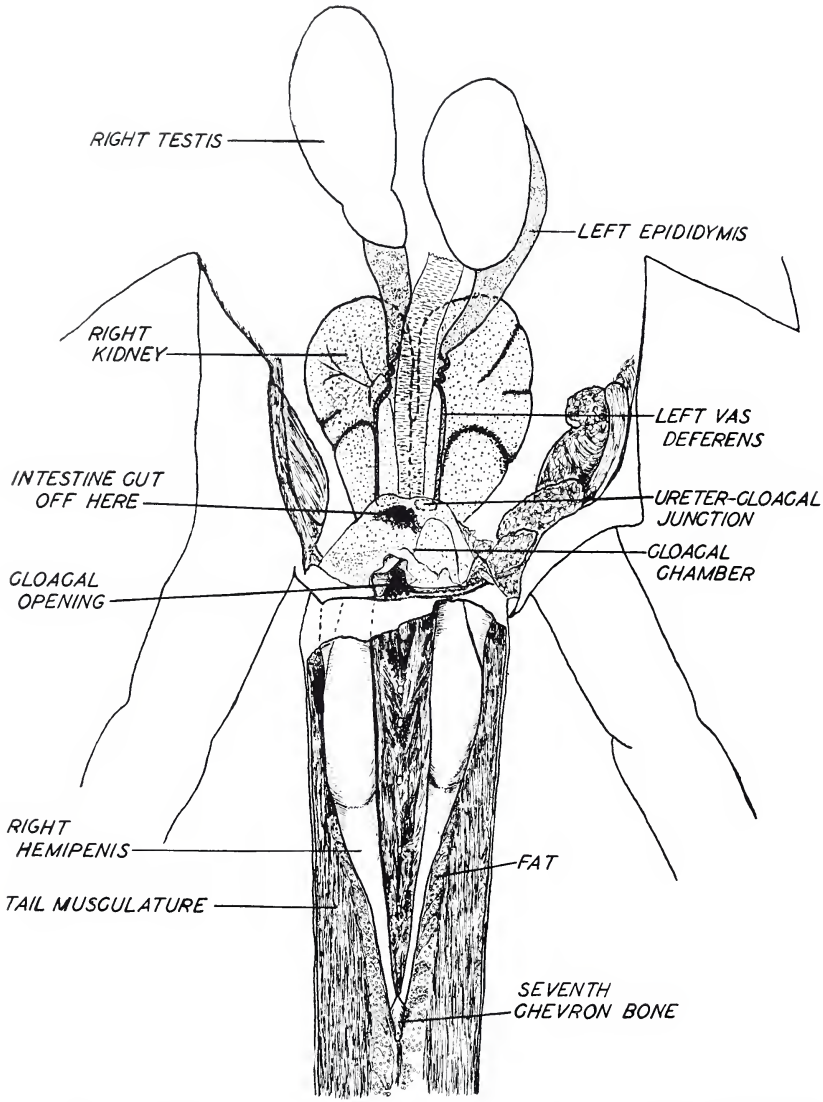

Fig. 3. Specimen No. 210 with viscera removed to reveal further the urogenital organs, and ventral side of tail removed to show hemipenial relations. (x3)

This report is concerned for the most part with the abdominal viscera and the urogenital system in the male. Emphasis was laid on organ relations.

Literature

Accounts of lizard anatomy are not numerous in English, as Davis (1934) implies. Volume II of Parker and Haswell's (1930) text contains

a discussion based on the European genus Lacerta, and chiefly on *L. viridis*. On American forms Adams (1938) gives figures and a brief description of the iguanid Sceloporus, and Davis (1934) has written a laboratory guide on another iguanid, Crotaphytus. Probably the most comprehensive reference work on lizard anatomy is that of C. K. Hoffman, in the old classic, Bronn's *Thierreich*. The excellent account of

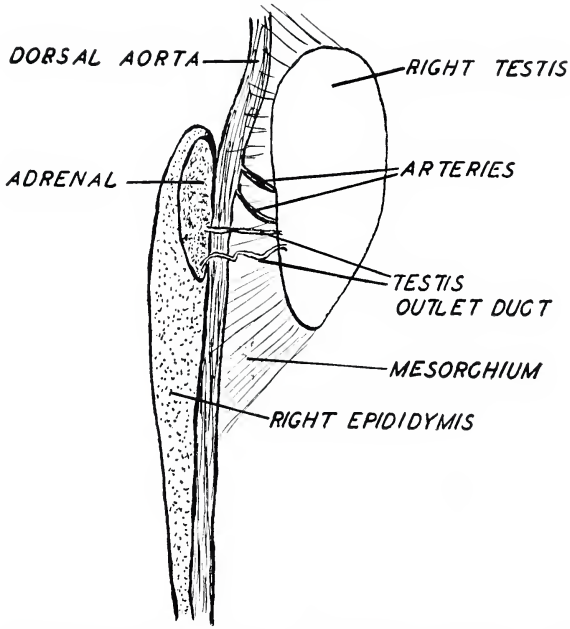

Fig. 4. Right testis of *E. fasciatus* No. 53 displaced to the left, to illustrate testicular blood supply and relations of adrenal gland, epididymis, dorsal aorta, and testis. (x5)

Kraus (1921) is based on *Lacerta agilis* and is written from the standpoint of histology but contains much gross anatomical material. A most exhaustive treatment, when completed, will be that of Bolk et al (1931), and Kükenthal (1931) bases discussion on the interesting primitive lizard, Sphenodon.

Observations

General arrangement of parts.—When the coelom or pleuro-peritoneal cavity is opened as described above, a typically vertebrate arrangement of parts is seen. The sections below describe these parts in more accurate terms.

1. Heart, lungs, trachea.—In the anterior end of such a dissection the removal of muscle and bone of the pectoral region reveals that the heart lies directly dorsal to the pectoral girdle. The lungs join the bronchial tubes just dorsal to the heart. The trachea is quite long, its walls containing the characteristic cartilaginous rings. It extends anteriorly ventral to the oesophagus.

The lungs arise at the junction with bronchical tubes, at the heart level, and extend posteriorly into the coelomic cavity (Fig. 1). In animal No. 4 the total length of the lungs is 11.0 mm., their posterior terminations lying 4.0 mm. posterior to the origin of the cardiac end of the stomach.

2. **The digestive tube.**—The oesophagus lies in the median line in a somewhat dorsal position, running anteriorly dorsal to the trachea and being flanked by the lungs posteriorly. The oesophagus enlarges to form cardiac stomach at a point 4.0 mm. anterior to the posterior tip of the lungs in animal No. 4 (Fig. 1).

From the above-mentioned origin of cardiac stomach to the pyloric sphincter, the stomach of No. 4 is 15.0 mm. in length. Specific stomach shape is subject to considerable variation; in general, however, the greatest diameter is near the cardiac end, with a gradual decrease of diameter to the pylorus. The stomach of No. 210 (Fig. 2) conforms to this; that of No. 4 (Fig. 1) is somewhat modified. In No. 4 the stomach lies somewhat to the left of the median line, and almost antero-posteriorly. In No. 210 (Fig. 2), it lies more obliquely. A slight obliqueness of stomach position, from anterior left to posterior right, is the general rule. Exaggerated obliqueness is generally more illusory than real because of differential curvature. The lateral surface of greater curvature may be fairly oblique, especially posteriorly; the medial surface of lesser curvature is much less oblique.

The pylorus is usually evident as a constriction terminating the stomach. The posterior edge of the intestinal tube here is 4.3 mm. anterior to the anterior edge of the kidneys in No. 210 and 16.8 mm. anterior to the ventro-anterior lip of the anus.

From the pylorus the initial part of the small intestine, the duodenum, extends forward, forming with the stomach the J-shaped loop characteristic of vertebrates. The duodenum extends as far forward as the posterior limit of the liver. The anterior edge of the tube at this point in No. 210 is 23.5 mm. anterior to the ventro-anterior anal lip. Hence, it exhibits a difference in level, as compared with pylorus of 6.7 mm., which gives an approximate length for the duodenum. In No. 210 the outer edge of the duodenum is 7.3 mm. to the right of the body midline. (Fig. 2).

From the most anterior level near the liver, the ileum then extends backwards to the rectum. The ileum usually exhibits 2 or 3 loops or curves, the exact arrangement of which is variable, those shown in Figures 1 and 2 being characteristic. In No. 4 the combined length of small intestine, duodenum, and ileum is 24.0 mm. Diameters were not measured but are drawn to scale in the figures.

From the point where the ileum enlarges to form it to the point where it gives rise to the globular cloaca (Figs. 1, 2) the rectum is 9.0 mm. long in No. 4. It is 3.5 mm. in diameter near its posterior end in No. 54. In Lacerta, Parker (1884) and Parker and Haswell (1930) describe a caecum at the junction of ileum and rectum. Adams (1938) figures but does not describe such a caecum for Sceloporus. Davis (1934) mentions one for Crotaphytus as a thin walled enlargement. An asymmetry of rectal expansion is implied in these descriptions. I can find no

similar structure in Eumeces, and any caecal capacity here must be largely capacity for a symmetrical enlargement of the anterior end of the rectum (Fig. 2).

The cloaca is the most posterior region of the digestive tube, of functional significance as excurrent pathways for products not only of the digestive but also of reproductive and urinary systems as well. It is usually of greater diameter than the large intestine, often globular in shape. The study of its posterior chambers is properly a histological one and will be reported later. It opens to the exterior at the anus, a transverse slit (Fig. 1) having in No. 4 a maximum width of 5.5 mm. It coincides in level with the posterior borders of the limbs.

3. **Digestive glands.**—The pancreas is somewhat elongate, lying between the stomach and duodenum and extending forward toward the liver. The latter organ is conspicuous, occupying much coelomic space and ventrally located, thus overlying some organs when viewed ventrally (Fig. 1). In No. 4, from the most anterior tip on the left side of the liver to the posterior border of the same side, the measurement is 11.0 mm. and, from the same tip to the level of the most posterior tip on the right side (concealed by intestine, Fig. 1), 16.5 mm. In No. 210, the right lobe of the liver lies at the same level as the anterior extension of the duodenum, the central lobe terminates 4.3 mm. anterior to this, and the left lobe in turn is 2.8 mm. (with tip turned down, Fig. 2) longer than the central one. The width of the liver is approximately that of the coelomic cavity, tapering anteriorly.

4. **Testis.**—The compact cylindrical testis appears more or less oval when viewed ventrally. It is light yellow in color and lies suspended in the bilateral mesenteric fold, or mesorchium, close to the dorsal body wall.

The lizard testis seems to exhibit typically an asymmetry of anteroposterior level, the right one lying anterior to the left. Such is the case in Sceloporus (Adams, 1938), *L. viridis* (Parker, 1884), and *L. agilis* (Kraus, 1921). The testis of *Eumeces fasciatus* conforms to this scheme (Figs. 1 and 2). In No. 54, the posterior borders of the testis are 1.5 mm. apart in level. In No. 210, the posterior end of the right testis is 0.8 mm. anterior to the same end of the left, but because of greater length its anterior end is 3.0 mm. in front of the anterior end of the left.

Size, shape, and weight of the testis is subject to considerable variation, which is not only among individuals but may also be bilateral in the same individual. Thus, in No. 54, the right testis measures 4.9 mm. x 1.9 mm.; the left 5.0 mm. x 2.0 mm. In No. 210, the right testis is 10.0 mm. x 4.0 mm.; the left 7.4 mm. x 4.0 mm. (Fig. 2). The right testis of No. 53 is 5.0 mm. long.

The testis occupies a quite dorsal position, being overlaid only by the adrenal gland and part of the epididymis (Fig. 3; 4). In No. 53, the testicular blood supply consists of two small branches of the dorsal aorta, the anterior branch entering the testis 2.8 mm. from its anterior end. (Fig. 4) Bilaterally the testis lies with medial borders a short distance from the body midline, the lateral border of the left testis lying 5.0 mm. to the left of the median line in No. 210.

As to antero-posterior level, the testis lies near the pylorus (Fig. 1, No. 4) and near the anterior end of the rectum (Figs. 1, 2). The left testis of No. 54 lies 2.0 mm. in front of the anterior border of the left kidney. In No. 210, the posterior edge of the right testis is 1.9 mm., of the left testis 1.1 mm.; anterior to the foremost edge of the kidney. In the same animal the anterior edge of the left testis is 21.0 mm. anterior to the ventro-anterior lip of the anus, 8.5 mm. in front of the anterior edge of the kidneys, thus extending 4.2 mm. farther forward than the pyloric level (Fig. 2). The posterior edge of the right testis in No. 210 is 14.4 mm. in front of the same anal lip, the posterior edge of the left testis, 13.6 mm. These are then 2.4 mm. and 3.6 mm., respectively, from the pyloric level.

5. **Kidneys.**—The kidneys lie flush against the dorsal muscular body wall, far back posteriorly, in the usual retroperitoneal position. The anterior edge of the kidney, in No. 210, lies 12.5 mm. in front of the antero-ventral anal lip. Each single kidney may be likened to the shape of a right triangle, where the median edge forms a right angle with the anterior edge and the lateral edge forms the hypotenuse. The apex, represented by the posterior tip of the kidney, is far posterior, extending about 2.0 mm. to 3.0 mm. posterior to the level of the anus, lying imbedded in muscle close to the vertebral column. Morphologically the two kidneys are distinct anteriorly, but they become anatomically connected about midway of the length of the two kidneys. Indentations on the lateral edges and grooves on the ventral surfaces mark lobulations of each kidney (Fig. 3), which is a "true kidney" or metanephros.

In animal No. 54, the kidney extends to within 2.0 mm. of the posterior border of the left testis, and the greatest width of the left kidney is 2.5 mm. As indicated above, the kidney in No. 210 comes to within 1.9 mm. and 1.1 mm. of the respective right and left testes and 4.3 mm. of the duodenum. Also in No. 210, the front border of the kidneys extend 12.5 mm. anterior to the ventro-anterior anal lip; hence, they are about 14.5 mm. long to posterior tip. The front edge of the kidney in No. 210 is 8.5 mm. from the posterior edge of the left testis. A band of material is seen passing along covering the medial surfaces of the kidneys in No. 210 (Fig. 3) which consists of blood vessels, peritoneum, and cut mesenteric material.

6. **Other urogenital structures; the adrenal gland.**—The epididymis is fusiform in shape. It widens rapidly from the anterior end to a maximum, then narrows down more gradually to the origin from it of the vas deferens (Fig. 3). The organ is suspended in a fold of the mesorchium, dorsal and lateral to the testis. In animal No. 54, the anterior end of the epididymis is 0.8 mm. posterior to the front end of the right testis; in No. 53, this distance is 1.5 mm.; also on the right side. As seen from the ventral side, the organ emerges from under the lateral border of the left testis 2.3 mm. posterior to the anterior edge of the latter organ in No. 210. The maximum width of the right epididymis in No. 54 is 0.8 mm., and length of both epididymis and vas deferens is 7.8 mm., the two vasa deferentia entering the cloaca at points 1.8 mm. apart. The epididymis extends posteriorly, then obliquely across the anterior ventral

surface of the kidney; then it gives rise to the vas deferens. The latter tube exhibits a few convolutions at its anterior end, then extends posteriorly near the medial edge on the ventral surface of the kidney.

The adrenal gland, golden yellow in color, lies on the medio-ventral surface of the epididymis and is inseparably bound up in the epididymal capsule (Fig. 4).

The ureter is not easily observed, as it is not visible as a distinct tube. It arises at about the last convolution of the vas deferens, and extends as a ridge on the ventral renal surface medial to the vas deferens. It does not emerge as a definite tube to enter the cloaca, as cloacal wall and kidney surface are so closely approximated that an extremely short connection is effected (Fig. 3). Whether the ureter and vas deferens on a side unite before joining the cloaca was not determined.

7. **Hemipenis.**—The copulatory sac or hemipenis may be considered a posterior evagination of the cloacal wall. Surrounded by a sheath, the hemipenis lies among the muscles of the ventro-lateral region of the tail. Anteriorly the organ connects with the posterior cloacal wall near the ventro-lateral corners. At approximately half the total length posterior, the organ changes character, the posterior part undoubtedly being muscular, the anterior part the saccular intromittent organ itself. The entire organ slants medially and dorsally, finally effecting a connection with the seventh chevron bone of the tail. This must be associated with the eleventh caudal vertebra since Taylor (1935) states that chevron bones begin on the fourth caudal vertebra.

8. **Fat storage.**—The corpora adiposa are bilateral masses of fatty tissue lying at the approximate coelomic level of the anterior half of the kidney (Figs. 2, 3). These fat bodies are the usual yellow color and vary greatly in size and weight. Their position is latero-ventral, mostly in front of but partly lying under (dorsal to) the pubic part of the pelvic girdle. It may be of considerable interest to point out that in *E. fasciatus* the fat bodies may be outclassed by the tail as sites of fat deposition. Large masses of fat, segmentally laid down, were dissected from the tail region of No. 210 in preparing it for the drawing seen in Figure 3. Remaining fat is shown in the figure.

Summary

It has been demonstrated that the abdominal viscera and the urogenital system of *Eumeces fasciatus* is arranged in a typical vertebrate manner. The arrangement of these organs and part-to-part relationships have been described in rather exact terms and supplemented by the presentation of figures.

Literature Cited

Alverdes, Kurt, 1926. Die Samenableitungswegn der Eidechsen Zeitschr. f. mikroskopisch-anatopisch Forschung 6:420-442.

Adams, Leverett Allan, 1938. An introduction to the vertebrates. John Wiley. New York. Pp. 372-384.

Bolk, Göppert, Kallius, Lubosch, 1931. Handbuch der vergleichenden Anatomie der Wirbelthiere. Uran und Schwarzenburg.

Davis, D. Dwight, 1934. The collared lizard. A laboratory guide. Macmillan. New York.

Hoffman, C. K. Section on reptilia in Bronn's *Klassen und Ordnungen des Thierreichs.*

Kükenthal, Willy, 1931. Handbuch der Zoologie. Bd. 7. Berlin.

Kraus, Rudolph, 1921. Mikroskopische Anatomie der Wirbelthiere in einzel Darstellungen. II. Vogel und Reptilien. Pp. 412-433.

Parker, T. Jeffrey, 1884. Zootomy (vertebrates). Macmillan. London. **4.**

Parker, T. J., and Wm. A. Haswell. A textbook of zoology. Macmillan. London. 2:306-326.

Stejneger, Leonhard, and Thomas Barbour, 1939. Checklist of North American reptiles and amphibians. Harvard Univ. Press. Cambridge.

Taylor, Edward H., 1935. A taxonomic study of the cosmopolitan scincoid lizards of the genus Eumeces. Univ. Kansas Sci. Bull. **23**:1-643.